



Rua José Gomes Ferreira nº1, Arm. D
2660-360 São Julião do Tojal
Loures - Portugal

+351 210 966 988
www.ceramed.pt
ceramed@ceramed.pt



n-IBS®

NANO HYDROXYAPATITE INJECTABLE BONE SUBSTITUTE

RAW MATERIALS

- Chitosan
- Hydroxyapatite
- Biphasic Mixtures (HA+ β TCP)

MEDICAL DEVICES

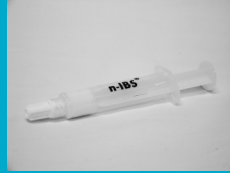- 3D Bone Substitutes
- Injectable Bone Substitutes
- Bone Cement
- Wound Dressing
- Membranes

COATINGS

- Hydroxyapatite (HA)
- Titanium (Ti)
- Double Layer (Ti+HA)
- Triple Layer (Ti+Ti+HA)
- PVD
- Anodizing

Ready to use injectable putty

n-IBS® is an injectable bone substitute composed of synthetic hydroxyapatite nano-particles



Specifications

Ready to use product

Hydroxyapatite nano-particles in aqueous suspension

Nano-particles diameter: 100nm

Nano-crystallite size: 10µm

Specific Surface area: 80m²/g

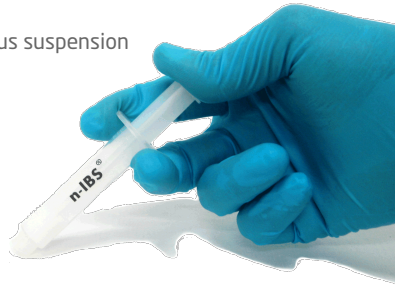Composition

Ceramic phase

Hydroxyapatite [Ca₁₀(PO₄)₆(OH)₂]


Aqueous Matrix

Water (H₂O)



Hydroxyapatite nano-particles putty

Mimics nano-structure of human inorganic bone, enhancing osseo-conductivity and -integration



n-IBS® can be used as a **STRUCTURAL SUPPORT** since it keeps a paste consistency during the regeneration process.

n-IBS® has enhanced **RESORPTION** due to its hydroxyapatite nano sized particles with increased surface area



n-IBS® is a
HIGH PURITY
paste

CASE #1

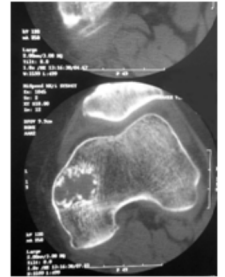
45 years old female with pain in anterior knee (radiological examinations did not discard the presence of endochondroma that may become sarcomatous).

Surgical procedure

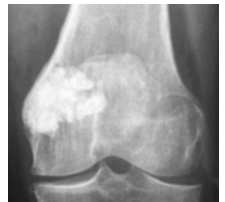
Aggressive curettage of the injury and filling bone void with n-IBS.

Follow up

- After 2 days in hospital, patient had authorization to perform load, using crutches as support radio-opaque tissue was visible;
- After 3 weeks the patient was discharged with good cicatrization and minor pain discomfort;
- At 12 weeks the bone substitute had established a direct contact with bone tissue with no presence of fibrosis. Homogeneous, progressive and centripetal bone neoformation was observed;
- After 1 year a complete resorption of bone substitute and a optimal and complete growth of new bone were observed



Pre-operative CAT scan



Post-operative CAT X-Ray

CASE #2

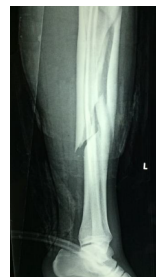Male with multifragmentar fracture of tibia and peroneus.

Surgical procedure

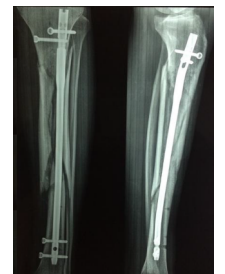Implant of intramedullary nail and total bone defect filling with n-IBS.

Follow up

- No signs of local infection or complications
- Normal cicatrization with bone substitute low resorption.
- New bone formation verified by radio-opaque tissue visibility.
- Clinical evaluation of the patient obtained by x-ray analysis reported as very good.



Pre-operative X-Ray



Post-operative X-Ray