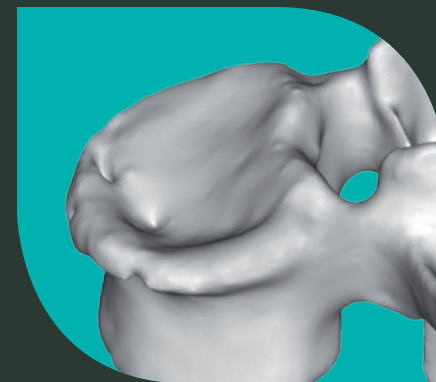


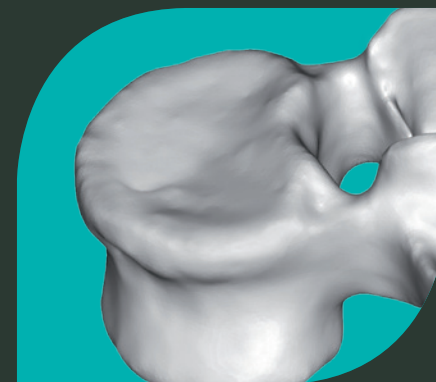SpineJack®

Controlled Anatomical Restoration


Pre-op



Post-op



vexim
REBALANCING SPINE



Controlled Anatomical Restoration

It is common practice for a fracture of any weight-bearing joint to first be reduced, then stabilised. The concept of SpineJack® is to achieve a biomechanical restoration to allow early mobilisation and weight bearing.

Anatomical reduction means restoration of the geometry of the whole vertebral body, that is, the cortical rings and endplates.

- ✗ Anatomical restoration consists of achieving sagittal and coronal balance; the key for kyphosis management and consecutive adjacent fracture avoidance.^{1,2,3,4,5,7}
- ✗ Vertebral endplate restoration has been described as having a positive influence on disc creeping, disc degeneration, compensatory curvatures or facet joint arthritis.^{1,6,8,9,10,11}

Several clinical and epidemiological studies have shown a correlation between vertebra deformation and clinical problems such as post-traumatic kyphosis, which has been depicted as a serious post-traumatic deformity.^{2,12} Within this context, Vexim has designed the SpineJack® implant to provide clinicians with a fully controlled and comprehensive solution for Vertebral Compression Fractures treatment enabling first, an anatomical reduction, and second, a safe stabilisation.

“Bring clinically and scientifically proven solutions to minimally invasive treatment of patients suffering from spinal trauma disorders”

SpineJack®

vexim
REBALANCING SPINE

- 1 **Oner F.C. & al.**
Changes in the disc space after fractures of the thoracolumbar spine - Journal of bone & joint surgery, 1998
- 2 **Oda I. & al.**
Does spinal kyphotic deformity influence the biomechanical characteristics of the adjacent motion segments - Spine, 2000
- 3 **Schlaich C. & al.**
Reduced pulmonary function in patients with spinal osteoporotic fractures - Osteoporos Int, 1998
- 4 **Lombardi I. & al.**
Evaluation of pulmonary function and quality of life in women with osteoporosis - Osteoporos Int, 2005
- 5 **Yang H.L. & al.**
Changes of pulmonary function for patients with osteoporotic vertebral compression fractures after kyphoplasty - Journal of Spinal Disorders & Techniques, 2007
- 6 **Tzermidianos MN et al.**
Altered disc pressure profile after an osteoporotic vertebral fracture is a risk factor for adjacent vertebral body fracture - European Spine Journal, 2008
- 7 **Wang XY et al.**
Kyphosis recurrence after posterior short-segment fixation in thoracolumbar burst fractures - Journal of Neurosurgery Spine (JNS), 2008
- 8 **Kerttula L.I. & al.**
Post-traumatic findings of the spine after earlier vertebral fracture in young patients: Clinical and MRI study - Spine, 2000
- 9 **Cinotti G. & al.**
Degenerative changes of porcine intervertebral disc induced by vertebral endplates injuries - Spine, 2005
- 10 **Brinckmann P. & al.**
The influence of vertebral body fracture, intradiscal injection, and partial discectomy on the radial bulge and height of human lumbar discs - Spine, 1985
- 11 **Malcolm BW et al.**
Post-traumatic Kyphosis. Journal of Bone and Joint Surgery (Am) 1981
- 12 **Whitesides TE.**
Traumatic kyphosis of the thoracolumbar spine. Clin. Orthop. 1977

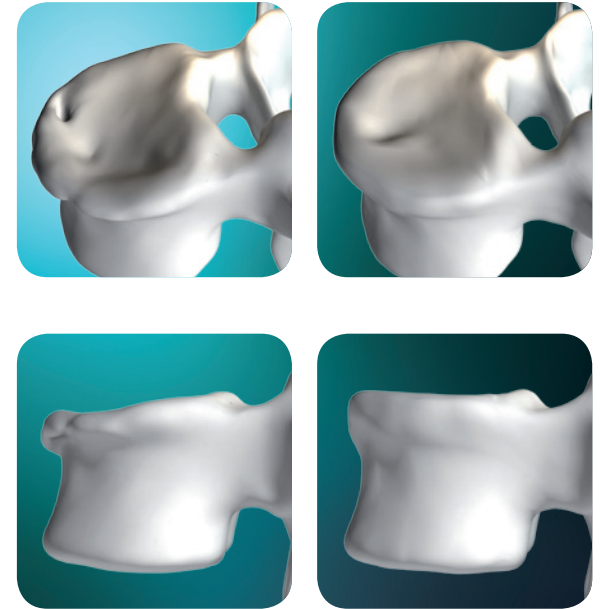
Anatomical Restoration

To achieve anatomical restoration after a vertebral compression fracture, the following should be considered:

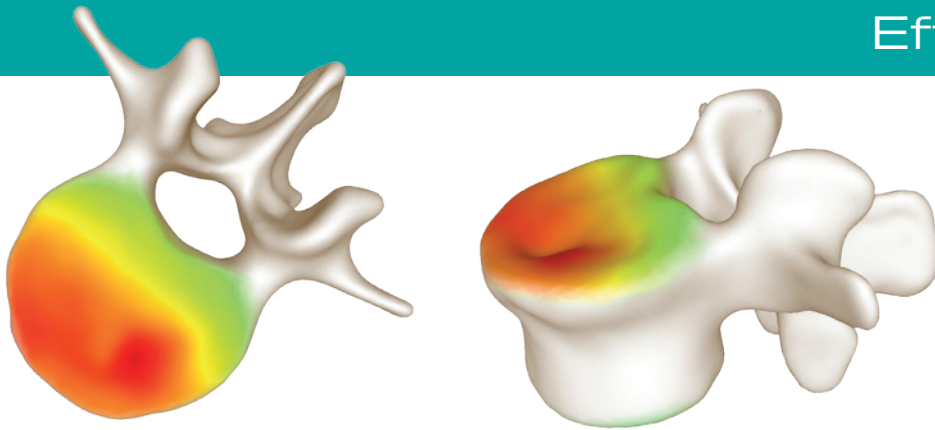
- ✕ Controlled uni-directional cranio-caudal expansion to restore sagittal and coronal balance
- ✕ Adaptation of implant's expansion to restore **coronal angulation**
- ✕ Adaptation of implant's positioning for **endplate restoration**

Back in Shape

AN OVERALL ANATOMICAL RESTORATION



Effective restoration measurement



Green = Lowest restoration, Red = Highest restoration

The restoration capability of SpineJack® has been proven using 3D reconstructions of pre and post-op CT scans. The superimposition of these images allows precise measurement of the vertebral body's anatomical restoration.

3D mapping with colour scale allows the visualisation of the amount of restoration.

Measure


SpineJack®

vexim
REBALANCING SPINE

1/ Implant positioning

Controlled by a specific instrumentation

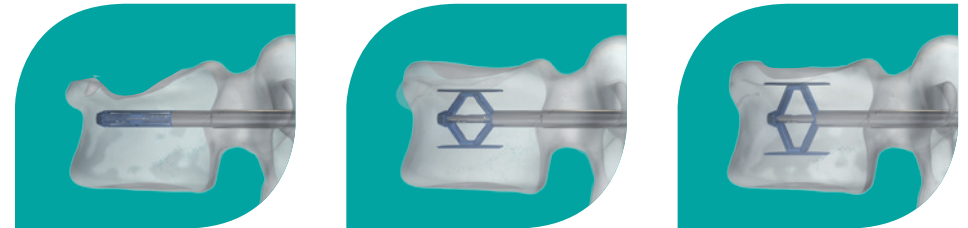
Implants' positioning in both sagittal and transverse planes can be achieved to a best fit for the fracture's shape and each patient anatomy.



2/ Implant expansion

Controlled by millimetric implants expansion

Millimetric expansion of the implant can be maintained until the biomaterial is injected.



A CONTINUUM IN CONTROL

3/ Optimal Biomaterial positioning and interdigitation

Controlled by Biomaterial fixed pathway and preservation of surrounding trabecular bone

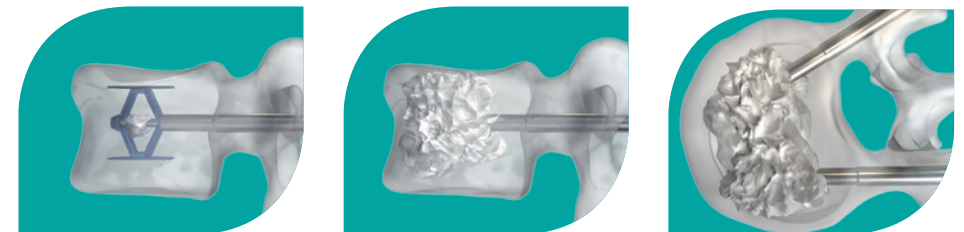Fixed pathway for the insertion of biomaterial through the implant helps minimize the risk of posterior leakage. Preserving the surrounding trabeculae by a cranio-caudal expansion allows for better interdigitation, thereby improving fixation and bone healing process.

Depending on the quality of the preserved trabecular structure, Vexim offers a range of injectable biomaterials:

- ✕ **Cohesion® Bone Cement**
- ✕ **Interface® Bone Fixation Composite**



Stabilise



SpineJack®

vexim
REBALANCING SPINE

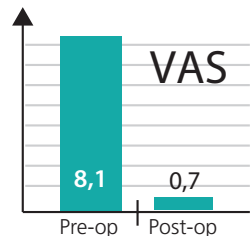
Clinical cases

TRAUMA

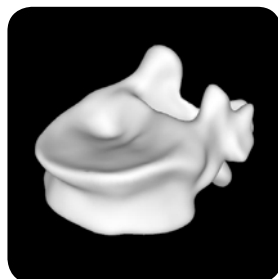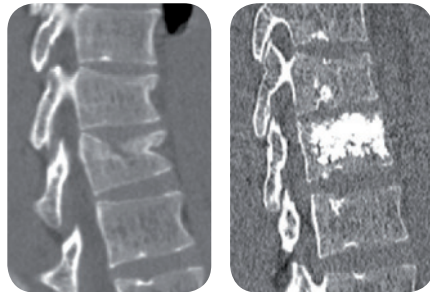
30-year-old patient

A.3.1. fracture in T12 after a fall from a ladder.

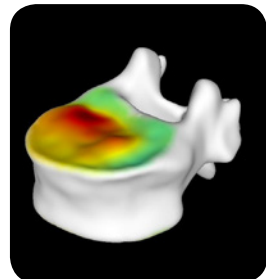
Surgery on fracture day + 5.



Hospital stay 3 days



Pre-op reconstruction

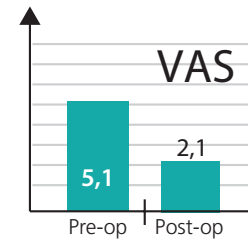


Post-op superior endplate reconstruction

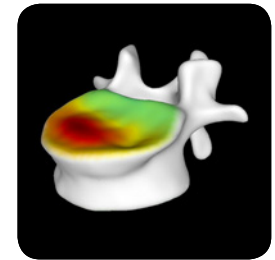
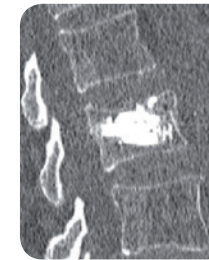
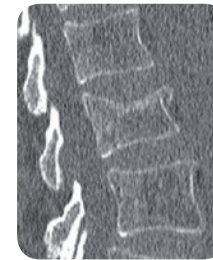OSTEOPOROTIC

80-year-old patient

Low energy trauma in osteoporotic bone, A.1.2 fracture in L1.



Hospital stay 2 days



Post-op superior endplate reconstruction

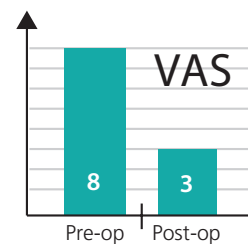
OSTEOPOROTIC

78-year-old patient

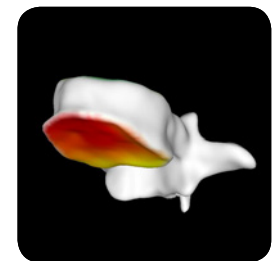
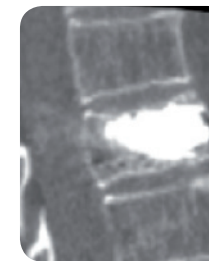
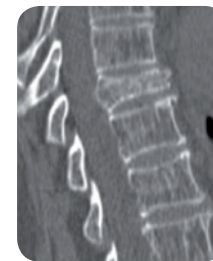After a fall accident patient suffered a A.3.1 fracture in T9.

Massive osteoporotic bone.

Surgery on fracture day + 4.



Hospital stay 4 days



Post-op inferior endplate reconstruction

VEXIM SA

Hills Plaza
8, Rue de Vidailhan - 1^{er} Etage
31130 Balma - France
Tel: +33(0)5.61.48.86.63
Fax: +33(0)5.61.48.95.19
E-mail: vexim@vexim.com



www.vexim.com