

# Translaminar Facet Screw Fixation

Rick C. Sasso, MD and Natalie M. Best, BS

*Indiana Spine Group, Indianapolis, IN*

## Introduction

Lumbar fusion has proven to be an accepted treatment for a variety of indications. Pedicle screw fixation has historically been the gold standard for providing stabilization to the lumbar motion segment while the fusion matures. However, numerous studies have reported high complication rates, increased pain, and juxtalevel degeneration due to the size of the pedicle screw instrumentation, the necessary wide soft tissue dissection, and exposure of the cephalad facet joint (4,7,10,13,25). These criticisms of pedicle screw fixation have necessitated more minimally invasive techniques and less bulky instrumentation.

Facet screw fixation was first described in 1948 by King (23). His technique involved short screws placed horizontally across the facet joint. (**Figure 1**) The screw enters the inferior articular process just medial to the joint and crosses the joint into the ipsilateral superior articular process. Improvements on this technique were made in 1959 by Boucher (5). His method used the same starting point as King, but the screw is directed more vertical into the base of the pedicle thereby increasing the length of screw in the caudal vertebrae. (**Figure 2**) Magerl changed the starting point of the screw to the junction of the contralateral spinous process and lamina. This translaminar technique described by Magerl in 1984 maximizes the strength and length of the screw both proximal and distal to the facet joint (26). (**Figure 3**) This technique involves a midline incision with dissection only out to the facet joints. The transverse processes and cephalad juxtalevel facet joints are not exposed. The screw used is

significantly longer than that used by both Boucher and King due to an entry point at the base of the contralateral spinous process. This improves the technique by increasing the effective working length of the screw on both sides of the facet joint resulting in increased strength of the fixation.

This review focuses on the advantages of translaminar facet screws as established in both the literature and in our experience. Translaminar facet instrumentation involves minimally invasive techniques without significant soft tissue dissection. Improvements over pedicle screw fixation have been shown in biomechanical stability and stiffness, complication rates, reoperation rates, operative time, blood loss, and patient perceived outcomes. Additionally, current intra-operative surgical image navigation techniques are rapidly improving which have increased the accuracy and decreased the operative time in placement of these screws.

## Biomechanics

Biomechanical and clinical studies have defined the benefits of Magerl's translaminar modification to the facet screw. Translaminar facet screws provide substantial biomechanical stability and rigidity to the instrumented segment. The first study evaluating the biomechanics of translaminar facet screws was by Kornblatt et al (24). Increased stiffness in static loading tests was determined. Heggeness and Esses substantiated these results with further biomechanical testing using repetitive cyclic compressive loads (17). The translaminar facet screws were able to maintain an increased

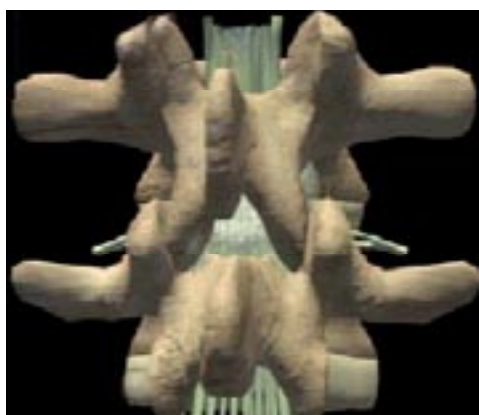

Figure 1: Facet screw fixation as described by King (1948). The short screw traverses horizontally across the joint from the inferior articular process of the cephalad vertebrae to the superior articular process of the inferior vertebrae.

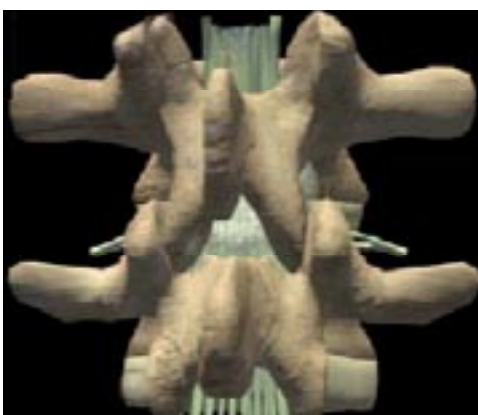

Figure 2: Boucher modification of King's facet screw (1959). The screw is aimed into the base of the pedicle thus increasing the length of the screw in the inferior vertebrae.

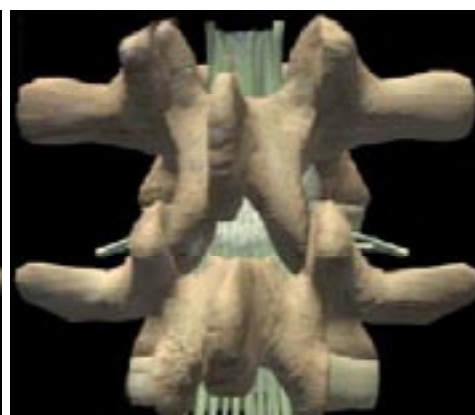

Figure 3: Magerl translaminar facet screw (1984). The entry point of the screw is at the junction of the spinous process and lamina of the contralateral side. The exit point is the base of the pedicle as in the Boucher technique.

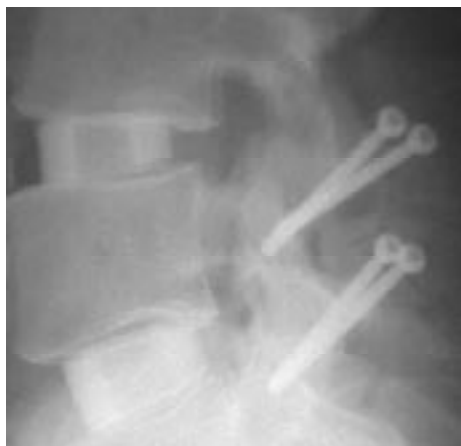

Figure 4: Lateral radiograph of two-level fusion with interbody graft and translaminar facet screws.

stiffness under cyclic loading (4 sec/cycle) after 5,000 cycles. Additionally, biomechanical comparisons have been made between pedicle screws and translaminar facet screws. Deguchi et al (9), found a statistically similar performance in the flexion-extension biomechanics of pedicle screws and translaminar facet screws. Ferrara et al showed similar results with comparable stability and mechanical fixation with less destruction than pedicle screws (11). Thus, the literature has shown that despite being less invasive and bulky, translaminar facet screws provide comparable stiffness, rigidity, and purchase in multiple biomechanical studies.

Although translaminar facet screws provide adequate stability in a stand-alone situation, they appear to be particularly beneficial when combined with a solid interbody graft. (**Figure 4**) In a human cadaveric model with interbody spacers, Ferrara et al compared pedicle screws and facet screws in short-term and long-term repetitive cycling (11). Both types of fixation provided significant improvements in stiffness and decreased range of motion compared to the intact specimens. No differences were found between the fixation techniques except under flexion loads where transfacet screws were actually statistically significantly stiffer than the traditional pedicle screw construct. Furthermore, these biomechanical advantages did not degrade with repetitive cycling. These authors concluded that despite the minimally invasive nature of the transfacet screws compared to the much bulkier pedicle screw and rod construct, they performed as well biomechanically when coupled with an interbody graft. In fact, in certain loading conditions, the facet screws provide better fixation than the pedicle screws. Thus, in a circumferential fusion with a structural interbody graft it is most reasonable to utilize a minimally invasive posterior instrumentation technique with translaminar facet fixation. This obviates the need for bulky pedicle screws and rods and decreases the "posterior fusion disease" associated with these larger constructs. Even if the pedicle screws and rods are placed percutaneously, they are still in very close proximity to the cephalad facet joint. The pedicle screw and rod construct may produce early juxtalevel degeneration by imping-

ing upon this cephalad facet complex. The bulk of the pedicle screw/rod construct also disrupts the normal function of the multifidus muscle much more than the translaminar facet screws. If the pedicles screws are placed in an open technique, the simple dissection of the multifidus muscle lateral to the superior articular process avulses the medial branch of the posterior primary ramus, thus denervating the multifidus. Furthermore, the cost of four poly-axial screws and two rods are much more than two simple, smaller screws.

## Clinical Experience

Superior clinical outcomes have also been established with translaminar facet screw fixation for lumbar fusion. Pseudarthrosis rates have ranged in the literature from 2-9% (15-17, 20, 21, 28). Early studies showed improvement in clinical results with decreased time to fusion and few technical difficulties (17, 21, 33). Humke et al reported a substantial decrease in pain scores following surgery with 92% of their patients stating they would repeat the same treatment again (20). Reich et al had similar results with 93.4% of their patients reporting a good-excellent outcome.<sup>17</sup> In comparison to the commonly performed pedicle screw technique, several studies have established the preference of translaminar facet screws due to their association with smaller incisions, ease of procedure, learning curve, less bulky instrumentation, and decreased cost (17, 28, 33, 12).

We evaluated a population of patients who underwent circumferential lumbar fusions comparing the reoperation rates of translaminar facet screws versus pedicle screws (3). From August 1993 to February 2003, 105 instrumented circumferential fusions with posterior fixation were performed and retrospectively studied. All procedures were performed by one orthopaedic spine surgeon. Out of these 105 patients, eighty-eight patients fit the initial inclusion criteria for the study which included less than a grade II spondylolisthesis and the anterior lumbar interbody fusion (ALIF) a femoral ring allograft. Adequate medical records were missing on 8 patients and thus were excluded. Eighty patients fit the above criteria. Only patients that had a follow-up of at least two years were included. Thirteen patients could not be reached for this follow-up and were excluded. Therefore, 67 patients were included for review. No exclusions were made due to age, sex, or medical conditions. Posterior instrumentation type was; 43 translaminar facet screw patients and 24 pedicle screw patients.

The technique for the posterior instrumentation and fusion included an intertransverse fusion for the pedicle screw group and a facet fusion for the facet screw group. All translaminar facet screws were placed percutaneously after a small midline incision exposed the spinous process, laminae and target facet joint.

## Data Collection

A retrospective review was done on all patients by examining their medical records. A comprehensive study was done recording demographic information, diagnosis including the

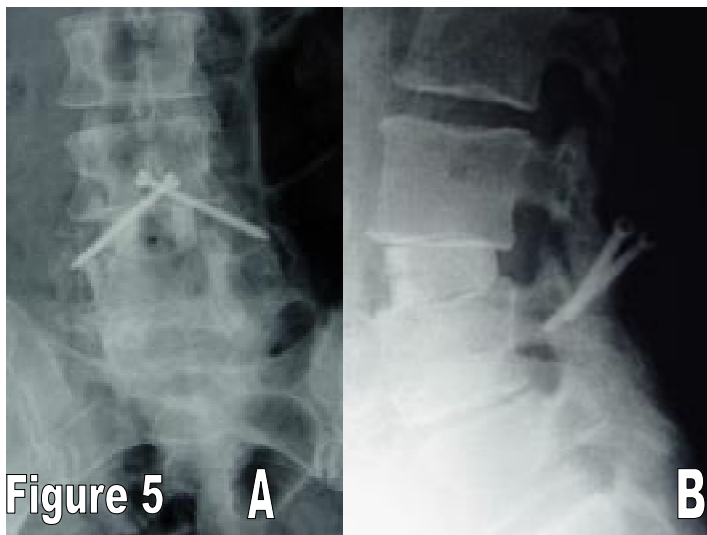


Figure 5: (A and B): A: AP x-ray of circumferential fusion L3-4 secondary to transitional syndrome above a solid L4-Sacrum fusion. Femoral ring allograft is anterior and translaminar facet screws posterior. B: Lateral x-ray of the ALIF and translaminar facet screws L3-4.

presence of spondylolisthesis, preoperative pain score on a 10-point visual analog scale (VAS), level of surgery, operative time, blood loss, and any complications including any subsequent operations. Adequate medical records could not be obtained on eight patients. These medical charts were unable to be located. Outcome was also determined through follow-up. Follow-ups were recorded in the office or from a telephone or mail questionnaire by an unbiased observer. Any subsequent surgeries were recorded along with a post-operative VAS pain rating. The average follow-up time for all patients was  $46.3 \pm 25.5$  months (Range=24-131 months). The pedicle screw patients had an average follow-up of  $62.1 \pm 35.3$  months, and the translaminar facet screw patients had an average follow-up of  $37.5 \pm 11.0$  months. 67 patients had at least a two-year follow-up. Post-operative pain VAS scores were recorded on 61 patients (91.0%). Follow-up questionnaires were not completed due to incorrect contact information or inability to reach the patient.

### Statistical Methods

Summary statistics (number, mean/frequency, standard deviation/percentage, and range) were provided for age, gender, spondylolisthesis, previous lumbosacral surgery, pre-operative VAS for pain, at the L5-S1 level, and number of levels fused. Summary statistics were listed for both the total patient population (80 patients) with adequate records and the patients with 2 year post-operative follow-up (67 patients). A frequency table was provided for the categorical variable of number of reoperations by type of device, either translaminar facet screws or pedicle screws. Fisher's exact test was used to test for an association between the number of reoperations and type of device. The odds ratio and 95% exact confidence interval were also calculated. The Mann-Whitney test was used to determine an association between VAS score and in-

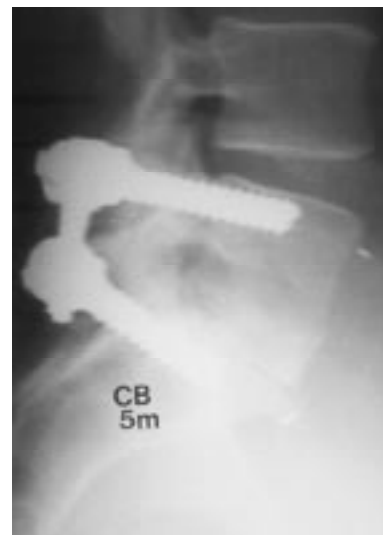

Figure 6: Lateral x-ray of circumferential fusion L5-S1 with femoral ring allograft anterior and pedicle screws and rods posterior.

strumentation type. A paired t-test was used to test for the mean difference between pre-operative and post-operative VAS. The 95% exact confidence interval was also calculated. The operative time and blood loss values were also compared between instrumentation populations using an unpaired t-test. P-values were recorded.

## Results

### Study Population

In the final study population, 67 patients were included. 43 patients (64.2%) had posterior fixation with translaminar facet screws, (Figure 5) and 24 (35.8%) had posterior fixation with pedicle screws. (Figure 6) Both procedures were interspersed, but translaminar facet screws were first used in April, 1999. Overall demographic characteristics of both device groups were similar considering the difference in population numbers.

### Occurrence of Reoperations

#### Instrumentation Type

Two out of the 43 patients (4.7%) with translaminar facet screw instrumentation had a second operation on the previously operated site whereas 9 of the 24 (37.5%) patients with pedicle screw instrumentation had a second operation. There was a significant association between type (translaminar facet screws versus pedicle screws) and occurrence of a reoperation ( $P = 0.0010$ ).

A patient went under a second operation due to continued or new pain, a possible pseudarthrosis, or pain from the instrumentation. All pedicle screw patients that had a second operation required exploration of the fusion mass and had their pedicle screws and rods removed due to continued or new pain after their index operation. It was determined from exploration that one patient (4.2%) did have a pseudarthrosis



**Table 1: Operative time and Blood loss**

	Translaminar Facet Screw Patients					Pedicle Screw Patients				
	N	Avg.	Min.	Max	Standard Deviation	N	Avg.	Min.	Max.	Standard Deviation
Operative Time	37	113.95	55	175	31.72	11	175.09	132	310	57.47
Unpaired t-test: $p=.0062$										
Blood Loss	43	137.25	10	400	140.81	22	321.82	100	1200	232.06
Unpaired t-test: $p=.0019$										

at the instrumented level. The two patients with translaminar facet screws, who had a subsequent operation, did not have their instrumentation removed. One patient had an exploration of the instrumented site without removing the instrumentation and was determined to have a solid fusion based on surgical exploration. The other patient had pedicle screws inserted without removing the facet screws and addition of an intertransverse fusion due to a pseudarthrosis. The average amount of time prior to reoperation was 18 months following the original procedure with a range of 7-30 months.

#### Previous Lumbosacral Procedure

22 patients (32.8%) of the total population had a previous decompression operation without fusion. Four (18%) of these patients had a reoperation to remove their instrumentation. This is not a significant difference ( $p=1.0000$ ) from those patients who had not had a previous lumbosacral surgery.

#### Multi-level Procedure

28 patients (41.8%) of the total population had more than 1 level fused; 25 were 2 levels, and 3 were 3 levels. 6 (21.4%) of these patients had a reoperation to remove their instrumentation. This is not a significant difference ( $p=.5054$ ) from those patients who had a one-level operation.

#### Operative Time and Blood Loss

The operative times and blood loss values are listed in **Table 1** by instrument type. The operative time was significantly lower in the translaminar facet screw population ( $p=.0062$ ) as was the blood loss ( $p=.0019$ ).

#### Other Complications

The only other complication that occurred was an infection of the surgical site. This occurred in one patient (4.2%) in the pedicle screw population and one patient (2.3%) in the translaminar facet screw population.

**Table 2: Functional Outcome**

Reported Surgical Outcome	Translaminar Facet Screw			Pedicle Screw		
	N	Frequency	Percentage/Std Dev	N	Frequency	Percentage/Std Dev
Pre-Operative VAS	42	8.1	2.0	11	9.0	0.96
Post-Operative VAS	42	4.2	2.8	19	5.2	3.1
Calculated Mean Difference (Pre-operative - Post-operative)	36	4.070, $p<.0001$		9	3.411, $p=.0158$	

#### Patient Reported Outcome

All 67 patients that were included in this study had a follow-up of at least one year either by an office visit or by a telephone or mail questionnaire. Based on pre-operative and post-operative pain VAS, a calculated mean difference between the post-operative VAS and the pre-operative VAS could be determined. For the translaminar facet screw patients, this mean difference was 4.070 ( $p<.0001$ ). This p-value indicates that the mean difference is indeed significantly different from zero. The pedicle screw patients had a VAS mean difference of 3.411 ( $p=.0158$ ). This p-value also indicates that the mean difference is significantly different from zero. There is not a significant association between VAS score and instrumentation type ( $p=.2499$ ). All patient-reported outcome results are detailed in **Table 2**.

Overall, in two comparable populations functional outcomes were better in the translaminar facet screw group compared to the pedicle screw set. Also, a significantly lower reoperation rate with lower operative time, blood loss, and complication rate was found in the translaminar facet screw population. At a minimum 2 year follow-up, subjective evaluation demonstrated a significant decrease in post-operative pain visual analog scores as compared to the pre-operative values ( $p<.0001$ ) (3).

Currently, the surgeon author of this review has completed 150 operations with translaminar facet screws on the lumbar spine from August, 1997 to September, 2005. Excellent success with no major complications has been seen.

#### Image Navigation

Recently, with the introduction of image-guided surgery techniques, the surgeon has had the ability to obtain simultaneous multilevel visualization intraoperatively both successfully and safely without the standard open exposure. Image navigation has been particularly effective for translaminar facet

screw fixation. Since translaminar facet screw fixation can be performed through a minimal exposure, virtual fluoroscopy allows the surgeon to place the screws through a series of stab incisions while still visualizing the spine with accurate placement. Many studies have shown low pedicle screw misplacement rates, low incidence of radiation exposure, and excellent operative field viewing with image-guided navigation.(1-2, 6, 8, 14, 18-19, 22, 27, 29, 30-31 ). Two studies have investigated the use of virtual fluoroscopy in translaminar facet screw placement. Both studies involved a technique where the translaminar facet screws were placed percutaneously through stab wounds under fluoroscopic guidance. Sasso et al<sup>33</sup> performed a human cadaveric study with a percutaneous reference frame. The results of the study showed acceptable placement with no screws placing the spinal canal or exiting nerve root at risk. Shim et al performed a similar study evaluating their clinical experience of 65 screws inserted under fluoroscopy (32). There was one complication in screw placement. A post-operative CT scan showed a fractured tip of a superior articular process of the sacrum. However, the path of the screw was not determined to be incorrect. These studies validate the use of translaminar facet screws under image navigation and fluoroscopy and established it as a technically feasible, safe, economical, and efficient method for stabilizing the posterior spine in a minimally invasive fashion.

## Discussion

Translaminar facet screws have a number of advantages over other posterior fixation techniques. They can be inserted in a minimally invasive fashion without significant dissection while maintaining a technically undemanding procedure. With the use of image navigation, the surgeon is able to visualize each spine segment with accuracy. This has proven to result in low screw misplacement rates and excellent operative field viewing.

Numerous studies have substantiated the biomechanical and clinical performance of translaminar facet screws. When indicated, translaminar facet screws provide the necessary stability for the lumbar spine. Translaminar facet screw fixation is a safe, uncomplicated, cost-effective, rigid construct that should be indicated in circumferential lumbar fusions.

## References

1. Assaker R, Reyns N, Vinchon M, et al. Transpedicular screw placement: image-guided versus lateral-view fluoroscopy: in vitro simulation. *Spine* 2001;26:E496-501.
2. Austin MS, Vaccaro AR, Brislin B, et al. Image-guided spine surgery: a cadaver study comparing conventional open laminoforaminotomy and two image-guided techniques for pedicle screw placement in posterolateral fusion and nonfusion models. *Spine* 2002;27:2503-8.
3. Best NM, Sasso RC. Efficacy of translaminar facet screw fixation in circumferential interbody fusions as compared to pedicle screw fixation. *J Spinal Disord*. Unpublished but accepted.
4. Blumenthal S, Gill K. Complications of the Wiltse pedicle screw fixation system. *Spine*. 1993;18:1867-71.
5. Boucher HH. A method of spinal fusion. *J Bone Joint Surg Br*. 1959;41:248-59.
6. Carbone JJ, Tortolani PJ, Quartararo LG. Fluoroscopically assisted pedicle screw fixation for thoracic and thoracolumbar injuries. *Spine* 2003;28:91-7.
7. Castro WH, Halm H, Jerosch J, et al. Accuracy of pedicle screw placement in lumbar vertebrae. *Spine*. 1996;21:1320-4.
8. Choi WW, Green BA, Levi AD. Computer-assisted fluoroscopic targeting system for pedicle screw insertion. *Neurosurgery* 2000;47:872-8.
9. Deguchi M, Cheng BC, Sato K, et al. Biomechanical evaluation of translaminar facet joint fixation: A comparative study of poly-lactide pins, screws, and pedicle fixation. *Spine*. 1998;23:1307-12.
10. Esses SI, Sachs BL, Dreyzin V. Complications associated with the technique of pedicle screw fixation. *Spine*. 1993;18:2231-9.
11. Ferrara LA, Secor JL, Byung-ho J, et al. A biomechanical comparison of facet screw fixation and pedicle screw fixation. *Spine*. 2003;28(12):1226-34.
12. Foley KT, Holly LT, Schwender JD. Minimally invasive lumbar fusion. *Spine*. 2003;28:S26-35.
13. Gertzbein SD, Robbins SE. Accuracy of pedicular screw placement in vivo. *Spine*. 1990;15:11-4.
14. Girardi FP, Cammisa FP Jr, Sandhu HS, et al. The placement of lumbar pedicle screws using computerized stereotactic guidance. *J Bone Joint Surg Br* 1999;81:825-9.
15. Grob D, Humke T. Translaminar screw fixation in the lumbar spine: Technique, indications, results. *Eur Spine J*. 1998;3:178-86.
16. Grob D, Rubeli M, Scheier HJG, et al. Translaminar screw fixation of the lumbar spine. *Int Orthop*. 1992;16:223-6.
17. Heggeness MH, Esses SI. Translaminar facet joint screw fixation for lumbar and lumbosacral fusion. *Spine*. 1991;16:S266-9S.
18. Hinsche AF, Giannoudis PV, Smith RM. Fluoroscopy-based multiplanar image guidance for insertion of sacroiliac screws. *Clin Orthop* 2002;395:135-44.
19. Holly LT, Foley KT. Intraoperative spinal navigation. *Spine* 2003;28:S54-61.
20. Humke T, Grob D, Dvorak J, et al. Translaminar screw fixation of the lumbar and lumbosacral spine: A 5-year follow-up. *Spine*. 1998;23:1180-4.
21. Jacobs RR, Montesano PX, Jackson RP. Enhancement of lumbar spine fusion of use of translaminar facet joint screws. *Spine*. 1989;14:12-5.
22. Kalfas IH, Kormos DW, Murphy MA, et al. Application of frameless stereotaxy to pedicle screw fixation of the spine. *J Neurosurg* 1995;83:641-7.
23. King D. Internal fixation for lumbosacral fusion. *J Bone Joint Surg Am*. 1948;30:560-5.
24. Kornblatt MD, Casey MP, Jacobs RR. Internal fixation in lumbosacral spine fusion: A biomechanical and clinical study. *Clin Orthop*. 1986;203:141-50.
25. Lonstein JE, Denis F, Perra JH. Complications associated with pedicle screws. *J Bone Joint Surg Am*. 1999;81:1519-28.
26. Magerl FP. Stabilization of the lower thoracic and lumbar spine with external skeletal fixation. *Clin Orthop*. 1984;189:125-41.
27. Nolte LP, Slomczykowski MA, Berlemann U, et al. A new approach to computer-aided spine surgery: fluoroscopy-based surgical navigation. *Eur Spine J* 2000;9(Suppl. 1):78-88.
28. Reich SM, Kuflik P, Neuwirth M. Translaminar facet screw fixation in lumbar spine fusion. *Spine*. 1993;18:444-9.

29. Resnick DK. Prospective comparison of virtual fluoroscopy to fluoroscopy and plain radiographs for placement of lumbar pedicle screws. *J Spinal Disord* 2003;3:254-60.
30. Sasso RC, Best NM, Potts EA. Percutaneous computer-assisted translaminar facet screw: an initial human cadaveric study. *Spine J* 2005;5:515-9.
31. Schwend RM, Dewire PJ, Kowalski JM. Accuracy of fluoroscopically assisted laser targeting of the cadaveric thoracic and lumbar spine to place transpedicular screws. *J Spinal Disord* 2000;13:412-8.
32. Shim CS, Lee S, Jung B, et al. Fluoroscopically assisted percutaneous translaminar facet screw fixation following anterior lumbar interbody fusion: Technical report. *Spine* 2005;30:838-43.
33. Stonecipher T, Wright S. Posterior lumbar interbody fusion with facet-screw fixation. *Spine*. 1989;14:468-71.
34. Thalgott JS, Chin AK, Ameriks JA, et al. Minimally invasive 360 degrees instrumented lumbar fusion. *Eur Spine J*. 2000;9S51-6.

### Editor's Comments

This manuscript elegantly demonstrates the safety and benefits of translaminar facet screw fixation and ALIF in selected cases of lumbosacral spondylolisthesis. The authors have also demonstrated that the technique was well tolerated. They demonstrated the advantages of this technique over pedicle screw fixation, including the lower price, a diminished operative time, the better clinical outcome, and the shorter learning curve.

However, they did not state information regarding the

indications and contraindications of this procedure, and the fusion rate.

The need for an accompanying ALIF to attain fusion seems to be the main drawback of this technique. I agree with the authors that this technique is an appropriate alternative to pedicle screw fixation in selected cases. However, the authors did not answer this question: "Why hasn't this technique become popular despite the aforementioned advantages".

*Sait Naderi, MD*