


M6^c

artificial cervical disc



M6-C Artificial Cervical Disc

Surgical Technique

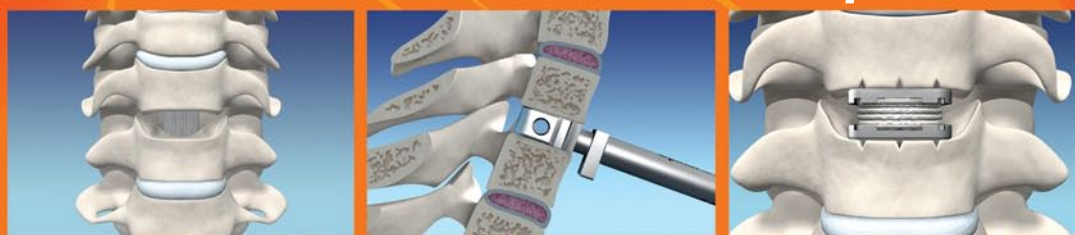


Table of Contents


The M6-C Artificial Cervical Disc	2
The M6-C System	3
Patient Positioning	4
Approach	5
Midline Identification and Placement of Retainer Pins	5
Discectomy and Decompression	5
Vertebral Endplate Preparation	6
Intervertebral Distraction	6
Re-assessment of Midline	6
Footprint Sizing	7
Trial Assessment: Disc Height	8
Trial Assessment: Midline Location	9
Realign C-arm to Lateral view	9
Keel Track Cutting	10
Loading the M6-C Cervical Disc	11
M6-C Cervical Disc Insertion	12
M6-C Multiple Level Technique	13
M6-C Cervical Disc Explantation	14

The M6-C Artificial Cervical Disc

The M6-C artificial cervical disc is designed to replicate the anatomic structure and biomechanical performance of a natural disc. Its innovative design incorporates an artificial nucleus to allow axial compression and a woven fiber annulus for controlled range of motion in all six degrees of freedom. The following surgical technique describes the steps for the implantation of the M6-C Artificial Cervical Disc.


The M6-C Artificial Cervical Disc System is intended to be used only by surgeons with training particular to the implant system, cervical spine surgery and related surgical techniques and biomechanical principles of the spine and spine arthroplasty.

CAUTION: Read and understand the M6-C artificial cervical disc system Instructions for Use prior to use.

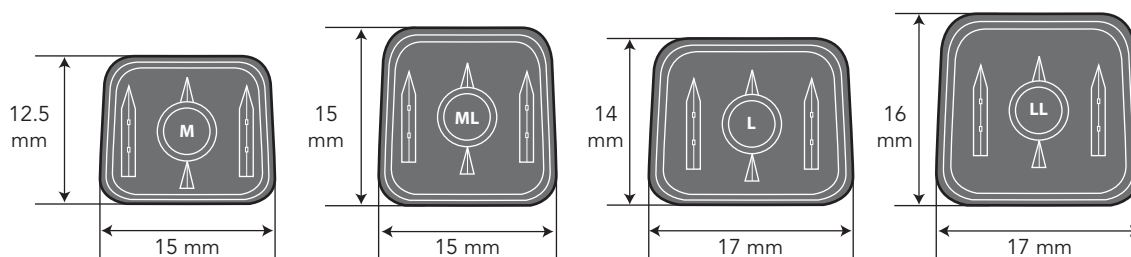


The M6-C System

M6-C Artificial Disc Heights & Footprint Sizes




Posterior



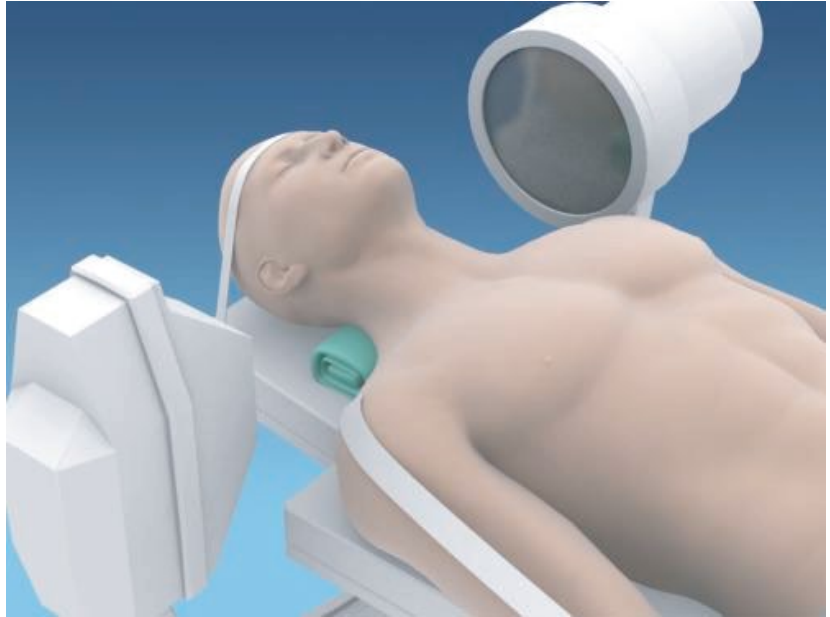
Anterior

M6-C Instruments



Patient Positioning

- Position the spine in a neutral position and support with a soft roll. Confirm via fluoroscopy that the spine is not in extension, flexion, or rotation.
- Secure or tape the head to prevent unwanted movement. The shoulders may be taped and pulled down for better visualization of the lower cervical spine.



Approach

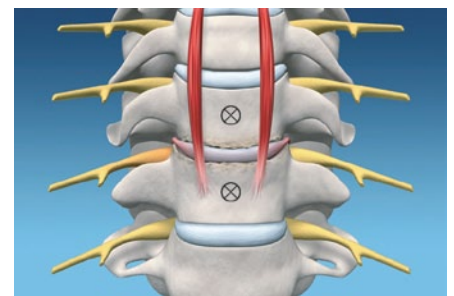
Using either a right or left-side approach and standard anterior cervical technique, dissect down to the treatment level(s), and confirm the desired disc space with fluoroscopy. Use careful dissection to preserve the longus colli muscles for use as an initial midline reference.

Midline Identification and Placement of Retainer Pins

Using AP and lateral fluoroscopic guidance, place the Cervical Retainer Pins into the adjacent vertebrae. Each pin should be inserted parallel to its respective endplate and in the midline. Select a Pin of sufficient length to obtain good bone purchase.

NOTE: If properly placed, the Cervical Retainer Pins can provide visual reference for midline and disc space trajectory for subsequent steps during implantation of the M6-C disc.

WARNING: Do not allow the Retainer Pins to progress beyond the posterior vertebral cortical rim. Allowing the Retainer Pins to progress beyond the posterior border of the vertebrae may result in patient injury.



Discectomy and Decompression

Perform discectomy to the posterior disc space, the lateral annulus and uncovertebral joints. A total, symmetrical decompression should be completed.

Vertebral Endplate Preparation

- Use rongeurs, punches and/or drills to remove anterior and posterior osteophytes.
- Use curettes or similar instruments to remove the cartilaginous endplates.

NOTE: Take care to preserve cortical bone and maintain endplate angles.

CAUTION: Excessive removal of endplate cortical bone may result in sub-optimal outcomes

Intervertebral Distraction

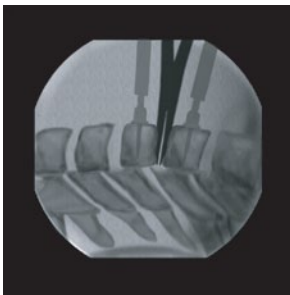


Fig. A

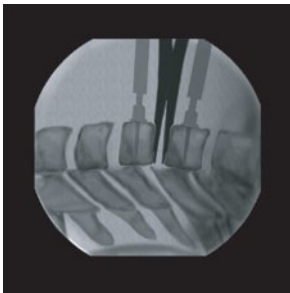


Fig. B

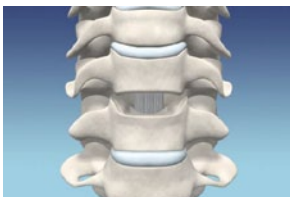

Fig. C

- With fluoroscopic guidance, use the Intervertebral Distractor to restore the desired height and to mobilize the treatment disc space as needed. (Fig. A, B)
- Use the Cervical Retainer to maintain the desired disc space height.

NOTE: To prevent abnormal disc space angles, do not use the Cervical Retainer alone to gain disc space height.

CAUTION: Take care not to over-distract the disc space.

WARNING: Do not allow the Intervertebral Distractor to progress more posteriorly than the posterior border of the vertebrae. Allowing the Intervertebral Distractor to progress beyond the posterior border of the vertebrae may result in patient injury.

Re-assessment of Midline

Visualize the medial aspect of the uncovertebral joints. Confirm that the Retainer Pins are in the midline as indicated by the point midway between the medial uncinate. If necessary, mark a corrected midline reference on the anterior vertebral bodies. (Fig. C)

Footprint Sizing

- With fluoroscopic guidance and visualization, use the Footprint Template to determine the correct size (Medium, Medium Long, Large, Large Long) M6-C Artificial Cervical Disc footprint. (Fig. A)
- Lay the Template onto the prepared vertebral endplates and determine which size provides maximum endplate coverage anterior to posterior. The posterior edge of the Template should come within 1-2 mm of the posterior vertebral border. (Fig. B)
- The Template should fit within the medial aspect of the uncovertebral joints, with good vertebral endplate contact.
- Slight symmetrical resection of the medial borders of the uncinate processes may need to be performed to allow the Footprint Template to fit correctly.

WARNING: Take care not to allow the Template to go beyond the posterior border of the vertebral bodies. Allowing the Template to go beyond the posterior border of the vertebral bodies may result in patient injury.

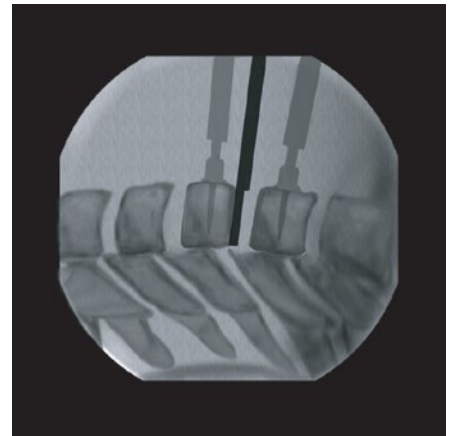


Fig. A




Fig. B

Trial Assessment: Disc Height




Fig. A - Misaligned C-arm



Fig. B - Properly aligned C-arm

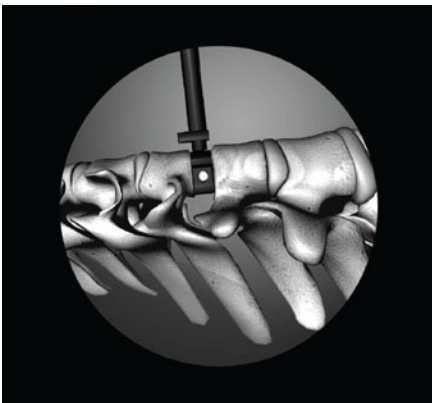

Fig. C - Trial in final position

- Relieve external distraction by releasing the Cervical Retainer.
- Align the Midline Marking Guide of the Trial to the midline. The Midline Marking Guide may be oriented either caudal or cephalad.
- Carefully insert the appropriate (Medium, Medium Long, Large, Large Long) 6mm Trial into the disc space under close fluoroscopic guidance. The correct size Trial will fit into the disc space with slight tapping.
- Stop the progress when the Trial is approximately halfway into the disc space. Use the Center Alignment Port (CAP™) to align the C-arm on plane to the disc space and the Trial. Once the C-arm is on plane, the CAP will become a complete circle. Continue Trial advancement while observing the progress on lateral fluoroscopy, until the posterior edge of the Trial is within 1-2mm of the posterior vertebral border. (Fig. A, B, C)

NOTE: The Trial should be positioned so that it rests on cortical bone.

- With the 6mm Trial in place, observe the treatment level disc space height, facet joints and spinous process and compare to adjacent levels. There should be good correlation of adjacent level height with the index level and no over-distraction of the disc space.
- If additional height is desired, repeat the above steps using the 7mm Trial.

NOTE: External distraction upon insertion of Trial may result in an over estimate of actual disc height.

WARNING: Fluoroscopic visualization must be maintained during the placement of the Trial. Do not allow the Trial to go beyond the posterior border of the vertebral bodies. Failure to visualize the Trial during this step could result in patient injury.

WARNING: Placement of the Trial beyond the posterior border of the vertebral bodies may result in patient injury.

Trial Assessment: Midline Location

- Remove the Handle from the Trial.
- Place the C-arm into A/P position and align to the spine using the spinous processes and lateral vertebral anatomy as a rotational reference. The Center Alignment Port (CAP) will allow quick angular alignment of the C-arm to the plane of the disc space. (Fig. A, B)
- Once the C-arm is aligned to the spine and disc space, use fluoroscopy to visualize the Trial in relation to the uncovertebral joints and confirm that it is in the midline.
- Make any necessary adjustments to the Trial with the C-arm in the A/P position. Use of the Short Trial Handle may facilitate adjustment without removing the C-arm.
- Use the electrocautery to mark the vertebrae at the center of the Midline Marking Guide if this position is different from previously determined locations. (Fig. C)

Realign C-arm to Lateral view

Before removing the Trial, return the C-arm to the lateral position and re-align to the lateral CAP. Lock the C-arm in this position. Use this C-arm position for the chisel and implant steps. (Fig. D)

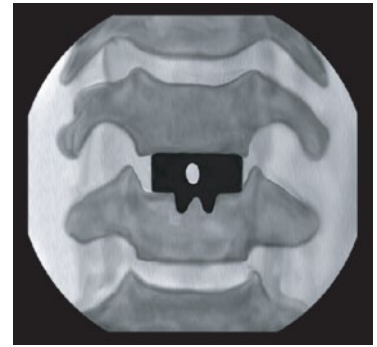


Fig. A - Misaligned C-arm

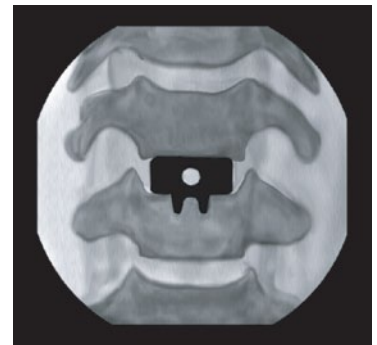

Fig. B - Properly aligned C-arm

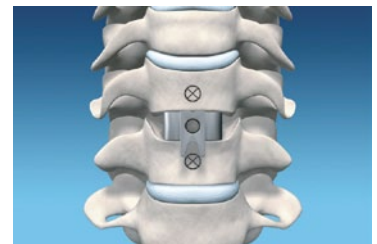

Fig. C




Fig. D

Keel Track Cutting

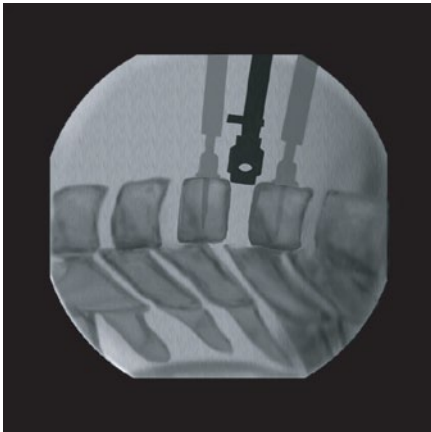


Fig. A - Misaligned CAP

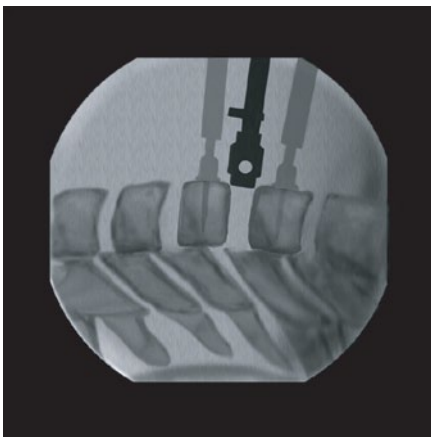


Fig. B - Properly aligned CAP

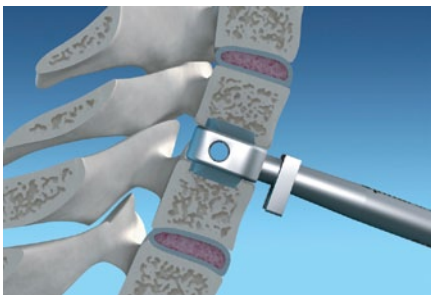


Fig. C

- Select the correct Chisel size based on the footprint and height sizing.
- Confirm that there is no additional external distraction applied.
- Align the Midline Marking Guide of the Chisel to the midline reference. Orient the Midline Marking Guide on the Chisel in the same caudal or cephalad direction as done with the Trial.
- Angle the handle of the Chisel to match the trajectory of the disc space as viewed on lateral plane fluoroscopy. If correctly aligned, the Retaining Pins can be used as a guide.
- With a fluoroscopic view, observe the lateral Center Alignment Port (CAP) of the Chisel and move the handle of the Chisel to the right or left to create a complete circle of the CAP. (Fig. A, B)
- Using fluoroscopic guidance, carefully tap the Chisel into the disc space while maintaining the midline and handle references previously made.
- Fluoroscopic imaging must be maintained during advancement of the Chisel. Take care to stop the Chisel when it reaches the same posterior position as the Trial in the previous step. (Fig. C)
- Remove the Chisel using the Slide Hammer.

NOTE: The final position of the Chisel will determine the position of the M6-C disc. Do not allow the Chisel to progress beyond the desired location of the M6-C disc.

WARNING: Allowing the Chisel to progress beyond the posterior border of the vertebral bodies may result in patient injury.

WARNING: Fluoroscopic visualization must be maintained during the advancement of the Chisel. Do not allow the Chisel to go beyond the posterior border of the vertebral bodies. Failure to visualize the Chisel during this step could result in patient injury.

Loading the M6-C Cervical Disc

- Select the appropriate Inserter. (Fig. A)
- Advance the inserter onto the disc. (Fig. B)
- Flip the toggle to release the disc from the Packaging Clip. (Fig. C)
- The M6-C is now loaded and ready to insert.

NOTE: The anterior edge of the Implant endplate must be flush against the Inserter. (Fig. D)



Fig. A



Fig. B



Fig. C




Fig. D

M6-C Cervical Disc Insertion

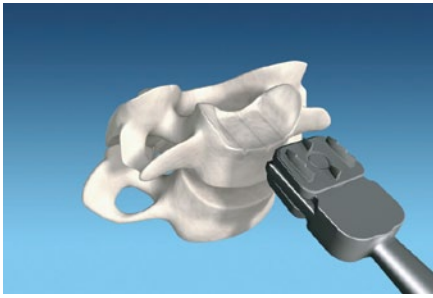


Fig. A

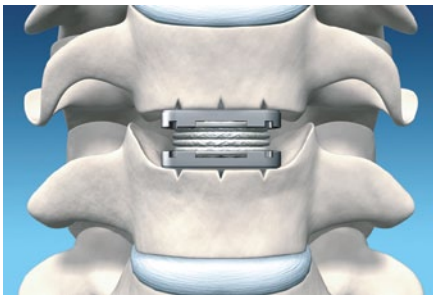


Fig. B

- Confirm that no additional external distraction is in place.
- Align the center keel of the M6-C to the middle keel track cut by the Chisel. Orient the handle of the Inserter to the trajectory of the disc space as viewed on lateral plane fluoroscopy. (Fig. A)
- Using fluoroscopic guidance, carefully tap the Inserter/M6-C into the disc space keeping the keels aligned to the cut keel tracks. (Fig. B)
- Continue carefully advancing the Inserter/M6-C while observing the progress via fluoroscopy until the posterior edge of the disc reaches the desired location.
- Verify that the M6-C is at the desired posterior position before removing the Inserter. Remove the Inserter while using a gentle right-to-left and pulling motion.
- Once the Inserter is removed, make a final assessment of positioning via lateral and A/P fluoroscopy.
- **Closing:** Close the wound following standard practices.

NOTE: If the Inserter must be re-attached for additional posterior placement, make sure that both upper and lower M6-C endplates are in good contact with the face of the Inserter. A slight amount of external distraction may be necessary to completely reattach the Inserter. Release the external distraction prior to attempting further positioning.

NOTE: The M6-C cannot be placed more posteriorly than the final posterior position obtained by the Chisel.

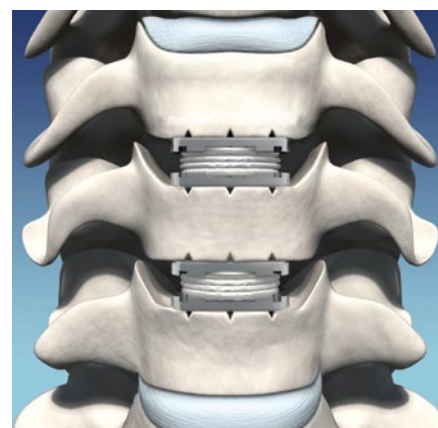
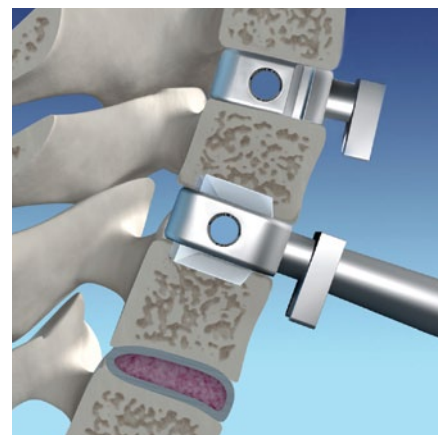
CAUTION: The M6-C cannot be repositioned anteriorly. Take care not to place the M6-C disc beyond the desired posterior position.

WARNING: Fluoroscopic visualization must be maintained during the insertion. Do not allow the Inserter to go beyond the posterior border of the vertebral bodies. Failure to visualize the Implant during this step could result in patient injury.

WARNING: Allowing the M6-C disc to progress beyond the posterior border of the vertebral bodies may result in patient injury.

M6-C Multiple Level Technique

- Follow the steps as described for patient positioning.
- Insert the Cervical Retainer Pins centrally within the vertebral bodies so that they will not interfere with the keels of the M6-C discs above or below. Follow the steps described for placement of the Cervical Retainer Pins.
- Depending on the severity of the involved levels, the surgeon may find it advantageous to perform discectomy and decompression on both levels prior to insertion of the first M6-C disc.
- Follow all steps for height restoration, disc space mobilization, endplate preparation, determination of footprint and disc height sizing for each level.
- If two discectomies are performed prior to M6-C disc insertion, an M6-C Trial may be placed into an empty disc space to serve as a spacer and stabilizer during work on the other level.
- Follow all steps for positioning the Trial, cutting keel tracks with the Chisel, and insertion of the M6-C disc.



M6-C Cervical Disc Explantation

If the M6-C Artificial Cervical Disc needs to be removed, the following steps should be utilized. After the removal of the Implant, the surgeon's clinical judgment will dictate the proper method for stabilizing the disc space.

- An anterior approach is used to access the involved level.
- Place the Cervical Retainer Pins into the adjacent vertebrae. Each pin should be inserted parallel to its respective endplate.
- Introduce gentle external distraction across the interspace.
- Cut through the outer sheath and artificial annulus of the M6-C disc to expose the polymer nucleus.
- Use rongeurs or forceps to remove the polymer nucleus.
- Carefully detach the titanium endplates from the vertebral endplates using elevators or other suitable instruments.
- Irrigate and suction to remove potential debris.

 This brochure was developed by
Spinal Kinetics, Inc., makers of the M6 artificial disc

© 2011 Spinal Kinetics, Inc. SPINAL KINETICS, MOTION FOR LIFE, M6, 6 DEGREES OF NATURAL FREEDOM, and the Spinal Kinetics Spine Logo are trademarks or registered trademarks of Spinal Kinetics, Inc. in the U.S. and in other countries. U.S. Patent No. 7,153,325; Pending U.S. and foreign patent applications.